

Correlation of Developmental Deformity with Calcium, Phosphorus, or Estradiol-17 β Levels in Reared Red Spotted Grouper, *Epinephelus akaara* Juveniles

Ji Eun Kim¹, Hyung Bae Kim², Young Don Lee³ and †Hea Ja Baek¹

¹Dept. of Marine Biology, Pukyong National University, Busan 48513, Korea

²Dept. of Marine Bio-Resources, Gangwon Provincial University, Gangnung 25425, Korea

³Marine Science Institute, Jeju National University, Korea

ABSTRACT : Skeletal deformities are significant problems that affect the growth and commercial value of fish reared in hatcheries. However, studies of bone metabolic process related to skeletal deformities are limited. We investigated the potential correlation between bone deformities and plasma calcium, phosphorus, and estradiol-17 β levels in reared red spotted grouper (*Epinephelus akaara*) juveniles. We collected *E. akaara* fry from private farms at 110, 140, 180 and 300 days after hatching (DAH), and classified the normal and deformed fish by observing their external shape and inner frame by soft X-ray. We also analyzed the calcium, phosphorous, and estradiol-17 β levels in their plasma. A comparison between normal and deformed fish, indicated that calcium and estradiol-17 β levels were higher in deformed fish than in the normal at 180 and 300 DAH. The level of phosphorus was also higher in deformed individuals than in normal fish, but only at 300 DAH. These results suggest that skeletal deformities are associated with increases in plasma calcium, phosphorus, and estradiol-17 β levels.

Key words : *Epinephelus akaara*, Skeletal deformity, Calcium, Phosphorus, Estradiol-17 β

INTRODUCTION

Aquaculture of high-value marine finfish species continues to develop rapidly in Korea. Grouper (members of the Family Serranidae, Subfamily epinephelinae) is one of the most commercially high-priced marine fish in the live fish markets (McGilvray & Chan, 2002). Particularly, the red spotted grouper, *Epinephelus akaara* (Temminck & Schlegel), has been recognized as economically important species in Korean Peninsula, Japan, China and Southeast Asian countries (Cho et al., 2015). Although many attempts

have been made to produce red spotted grouper larvae and juvenile due to high commercial value and consumer demand, high mortality in early life stages and high incidence of skeletal deformities are critical problems (Sugama & Ikenoue 1999; Song et al., 2005).

Marine fish larvae undergo major functional and morphological changes during successive developmental stages. Most malformations develop during early developmental stages. Therefore, skeletal deformities of marine fish larvae can affect successive development, decreasing their quality and commercial value (Cahu et al., 2003).

Manuscript received September 8, 2017, Received in revised form November 30, 2017, Accepted December 19, 2017

† Corresponding Author : Hea Ja Baek, Department of Marine Biology, Pukyong National University, Yongso-ro 45, Nam-gu, Busan 48513, Korea. Tel: +82-51-629-5924, Fax: +82-51-629-5931, E-mail: hjbaek@pknu.ac.kr

This is an Open Access article distributed under the terms of the Creative Commons Attribution Non-Commercial License (<http://creativecommons.org/licenses/by-nc/3.0>) which permits unrestricted non-commercial use, distribution, and reproduction in any medium, provided the original work is properly cited.

Lall & Lewis-McCrea (2007) suggested that deficiencies of some vitamins and certain minerals can be correlated with severe skeletal deformities in fish larvae under culture conditions. Particularly calcium and phosphorus in bone and blood have been used as indicators of development and maintenance of skeletal system. Calcium deficiency causes a delay in ontogeny of skeletal development and insufficient phosphorus leads to skeletal abnormalities (Fontagne et al., 2009). In addition, estrogen concentrations are closely linked to skeletal growth of fish (Sasayama, 1999; Persson et al., 1999; Suzuki et al., 2000).

Skeletal deformities were already described in other groupers, like seven-band grouper (*E. septemfasciatus*, Nagano et al., 2007), red (*E. akaara*, Setiadi et al., 2006; Park et al., 2016) or orange (*E. coioides*, Cruz-Lacierda et al., 2000) spotted groupers. Most studies in skeletal development of *E. akaara* have mainly focused on skeletal development; development of external morphology (Mito et al., 1967), development of fins and scales in larval and juvenile stages (Fukuhara & Fushimi, 1988), development of jaws and feeding (Kayano, 1988). However, little information has been reported on the skeletal deformity and bone mineralization, and their interactions with *E. akaara*. Therefore, objective of this study is to investigate the relationship between skeletal deformities and plasma calcium, phosphorus, and estradiol-17 β levels in red spotted grouper juveniles.

MATERIALS AND METHODS

1. Experimental fish

Red spotted grouper (at 110, 140, 180, 300 DAH) in four different groups were obtained from Marine Science Institute of Jeju National University. Mean total length and weight 6.97 \pm 0.15 cm and 5.87 \pm 0.10 g, 7.13 \pm 0.80 cm and 7.09 \pm 2.52 g, 8.29 \pm 0.66 cm and 8.75 \pm 1.80 g, 11.65 \pm 1.45 cm and 26.53 \pm 8.34 g (Table 1). The fish were reared in glass aquaria with running seawater of 34 \pm 0.5 ‰ at water tem-

Table 1. Biological characteristics of red spotted grouper, *Epinephelus akaara* in four groups used in this study

| Group | Days (DAH) | Total length (cm) | Total weight (g) |
|---------|------------|-------------------|------------------|
| Group 1 | 110 | 6.97 \pm 0.15 | 5.87 \pm 0.10 |
| Group 2 | 140 | 7.13 \pm 0.80 | 7.09 \pm 2.52 |
| Group 3 | 180 | 8.29 \pm 0.66 | 8.75 \pm 1.80 |
| Group 4 | 300 | 11.65 \pm 1.45 | 26.53 \pm 8.34 |

perature of 15.0 \pm 1.0 $^{\circ}$ C. The fish were fed artificial feed twice a day, but were not feed 24 h prior to the experiment. During the experimental period, the salinity, dissolved oxygen, and pH were maintained at 34 \pm 0.5 ‰, 6.5 \pm 1.0 mg/L, and 7.8 \pm 0.3, respectively. We classified red spotted grouper juveniles depending on the occurrence of deformity. For physiological analysis, blood was taken immediately from caudal vein with a heparinized 1 mL syringe. A total of 83-170 samples were taken in each groups.

2. Skeletal structure analyses

For osteological observation on external shape, the specimens were photographed from left lateral view using a digital camera (NIKON D300s, Nikon Co., Japan) with a resolution of 12.3 megapixels. Fish were classified by the criteria of the appearance of macroscopically visible body deformations. In addition, the specimens were used for observation of skeletal structures by soft X-ray photographs (SFX-130, SOFTEX Co., Japan).

3. Biochemical analyses

Collected blood was centrifuged for 15 min at 13,000 rpm at 4 $^{\circ}$ C. Total plasma calcium and phosphorus in normal and malformed fish were measured respectively using biochemistry automatic analyzer (FUJI DRI-CHEM NX 500i, Fujifilm Co., Japan). Plasma estradiol-17 β (E2) level was measured by radioimmunoassay (RIA) according to

the Kobayashi's method (Kobayashi & Mikuni, 1987). Antiserum for E2 was purchased from Cosmo-Bio Co., Ltd. (Tokyo, Japan). Radio-labeled steroids ([2,4,6,7-³H]-E2) was purchased from Amersham Lifesciences (England). For the assay, steroids from plasma were extracted twice in 2 mL diethyl ether, dried under nitrogen gas and were dissolved in 0.1% gel-PBS.

4. Statistical analyses

All data were expressed in means with the standard error of the means (SEM). Data analyses were based on *t*-test and Duncan test after assessing normality and homogeneity of variances using SPSS 18.0 and significance ascribed to differences at the 0.05 level.

RESULTS

1. Deformity pattern and incidence

There were different deformity types in *E. akaara*. Morphometric analysis of skeleton in red spotted grouper are presented in Fig. 1. The cephalic (Fig. 1-B), vertebral (Fig. 1-C), opercular (Fig. 1-D) deformity and complication (Fig. 1-E) occurred most frequently in deformed *E. akaara* (Fig. 1). The incident rate of normal and deformed fish was shown in Table 2. Results of normal were 80.5% of group 1 (110 days), 78.1% of group 2 (140 days), 76.1% of group 3 (180 days), and 75.0% of group 4 (300 days). The incidence depending on deformity patterns showed 6.1%, 4.3%, 4.3%, and 3.0% of cephalus, 4.9%, 2.4%, 4.3% and




Fig. 1. Photographs and X-ray radiographs of normal and deformed red spotted grouper, *Epinephelus akaara*. Normal and abnormal specimens were photographed and were used for observation by soft x-ray photographs. The pictures presented representative deformity pattern in red spotted grouper. A: Normal; B: Cephalic deformity; C: Vertebral deformity; D: Opercular deformity; E: Complication. Arrows indicates the place of deformity.

Table 2. The incidence of external and interior deformity in red spotted grouper, *Epinephelus akaara*.

| Category | Incidence (%) | | | |
|------------------------|----------------------|----------------------|----------------------|----------------------|
| | Group 1 (110 DAH) | Group 2 (140 DAH) | Group 3 (180 DAH) | Group 4 (300 DAH) |
| Normal | 80.5 | 78.1 | 76.1 | 75.0 |
| Deformity in head | 6.1 | 4.3 | 4.3 | 3.0 |
| Deformity in vertebrae | 4.9 | 2.4 | 4.3 | 4.0 |
| Deformity in operculum | 4.9 | 8.5 | 5.1 | 8.0 |
| Complication | 3.6 | 1.8 | 8.5 | 5.0 |
| Etc. | 0 | 4.9 | 1.7 | 5.0 |

4.0% of deformity in vertebrae, 4.9%, 8.5%, 5.1% and 8.0% of operculum, 3.6%, 1.8%, 8.5% and 5.0% of complication deformational symptoms in group 1, group 2, group 3, and group 4 respectively in red spotted grouper, *E. akaara*.

2. Calcium levels in plasma

Plasma calcium levels between normal and deformed fish at 140, 180 and 300 days after hatching, are presented in Fig. 2. In comparison between normal and de-

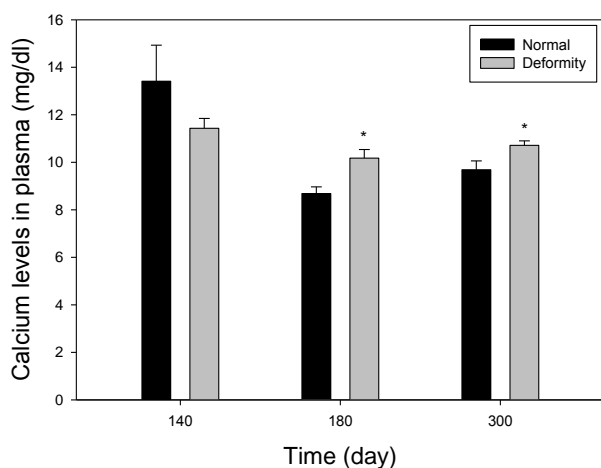


Fig. 2. Plasma calcium levels in normal and deformed individuals of different age groups of the red spotted grouper. Values are presented as the mean ± SEM. Data were analyzed using *t*-test ($P < 0.05$).

formed fish, it was found that deformed fish had higher calcium levels in plasma than did the normal fish, particularly at 180 days and 300 days (groups 3 and 4). In group 3, calcium levels were 8.69±0.28 mg/dL in normal, 10.23±0.36 mg/dL in deformed fish of *E. akaara* and in group 4, calcium levels were 9.69±0.37 mg/dL in normal, 10.71±0.19 mg/dL in deformed fish respectively. In both groups, calcium levels in deformity group were significantly higher than those in the normal ($P < 0.05$). On the other hand, in group 2 (at 140 days) calcium concentrations of the grouper with deformities was 11.43±0.41 mg/dL and the normal was 13.42±1.52 mg/dl. There were no differences in deformity and normal ($P > 0.05$). At 110 days, size of the fish was too small to collect blood, so we could not proceed.

3. Phosphorus levels in plasma

Plasma phosphorus levels between normal and deformed fish at 140, 180 and 300 days after hatching, are presented in Fig. 3. Compared to the normal *E. akaara*, the deformed fish had higher values in phosphorus at group 4. Phosphorus levels were 10.81±0.19 mg/dL in the normal, 12.70±0.71 mg/dL in abnormal. The only level of phosphorus in deformity was significantly higher than normal at 300 days ($P < 0.05$). However, in group 2 and 3, phosphorus levels of

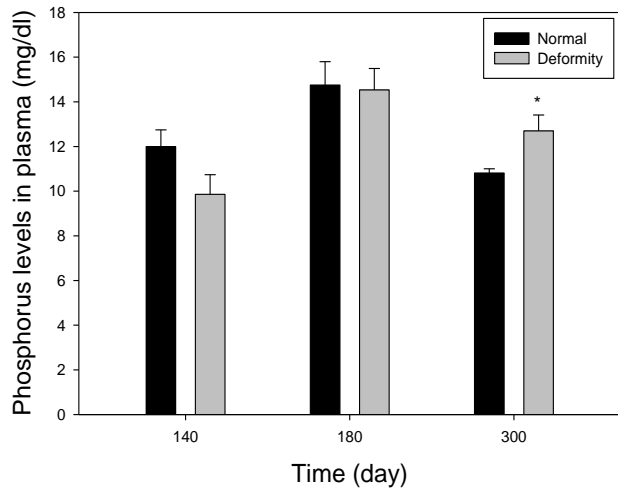


Fig. 3. Plasma phosphorus levels in normal and deformed individuals of different age groups of the red spotted grouper. Values are presented as the mean±SEM. Data were analyzed using *t*-test ($P < 0.05$).

fish with deformity were 9.86 ± 0.88 , 14.53 ± 0.96 mg/dL and normal fish had 12 ± 0.74 mg/dL, 14.75 ± 1.05 mg/dL phosphorus level. There were no statistical differences in normal and deformed fish ($P > 0.05$). At 110 days, size of the fish was too small to collect blood, so we could not proceed.

4. Estradiol-17 β levels in plasma

Plasma estradiol-17 β levels between normal and deformed fish at 180 and 300 days after hatching, are presented in Fig. 4. The level of estradiol-17 β in the deformed fish was statistically higher than those in the normal particularly in the group 3 and 4. In group 3, there were 0.124 ± 0.004 ng/mL and 0.115 ± 0.004 ng/mL of estradiol-17 β levels in deformed and normal fish, respectively. At 180 days, the level of estradiol-17 β in normal was lower than abnormal individuals ($P < 0.05$). In group 4, the levels of deformity were 0.168 ± 0.011 ng/mL and the normal fish had much lower estradiol-17 β level (0.119 ± 0.004 ng/mL) compared to deformed fish, as well ($P < 0.05$). The fish size at 110 days was too small to collect blood and the volume of blood at 140 days was too small to analysis, so we could

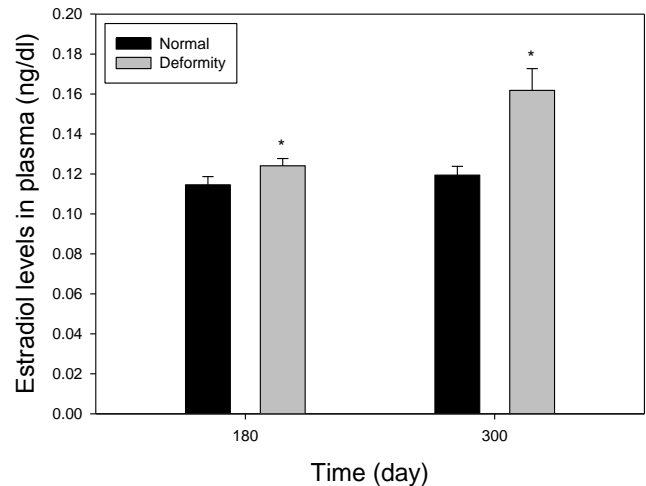


Fig. 4. Plasma estradiol-17 β levels in normal and deformed individuals of different age groups of the red spotted grouper. Values are presented as the mean±SEM. Data were analyzed using *t*-test ($P < 0.05$).

not proceed.

DISCUSSIONS

One of the most common issues in many cultured fish species is the high rate of body deformities (Barahona-Fernandes, 1982). Common skeletal deformities include curved vertebrae and soft bones in Atlantic salmon (Bæverfjord et al., 1998), deformities with head in frontal bones of common carp (Ogino & Takeda, 1976), and compressed vertebral bodies resulting in scoliosis in haddock (Roy & Lall, 2003) and halibut (Lewis-McCrea & Lall, 2007). In our study, the representative feature of deformation of *E. akaara* was observed mainly in head, spinal column, operculum and complex mixture.

Lall & Lewis-McCrea (2007) reported that the skeleton in fish undergoes continuous remodeling cycle during their life. In this process, calcium, phosphate, and other ions exchange continuously in blood and extracellular fluids. Our study shows that there were correlation especially between calcium, phosphate and estradiol-17 β levels in plasma of normal and deformity in particular develop-

mental stage. At 140 days after hatching of red spotted grouper (group 2), there were similarities of calcium and phosphorus concentrations in blood plasma in normal and deformed groups. However, it was found that calcium, phosphorus and estradiol-17 β level in abnormal fish was mostly higher than normal *E. akaara* at 180 and 300 days (group 3 and 4). According to Lall & Lewis-McCrea (2007), in bone metabolism of fish, vitamin D₃ stimulates absorption of calcium and phosphorus in intestine and kidney. This may also affect the relationship of calcium and phosphorus in blood and bone. If the level of calcium or phosphorus in blood is low, those in bone flow to blood for maintain a constant level, and vice versa. This may cause improper bone formation, abnormalities. Also, according to Gurerreiro et al., (2002), the increase of estradiol-17 β level is accompanied by increase of blood plasma calcium and phosphorus. In the present study, calcium and estradiol-17 β levels in the deformed fish were higher than those in the normal at 180 and 300 days. The level of phosphorus in the deformity was significantly higher than normal at 300 days. Roy & Lall (2003) observed that phosphorus deficiency is highly associated with bone deformity in haddock. In contrast to the present study, Van Den Avyle et al. (1989) reported that smallmouth bass had similarities of calcium and phosphorus concentrations in blood plasma of deformed and normal fish. However, the metabolism of bone is poorly demonstrated.

The present study suggests that the relationship of the chemical process in bone could be correlated with skeletal deformities from about 180 days in *E. akaara*. Moreover, it can be appeared that the result; plasma mineral determinations can be useful indicators of metabolic processes that affect bone formation (Van Den Avyle et al., 1989). However, the properties of malformation during various developmental stages are limited by the lack of information. Therefore, more study of skeletal metabolism which is involved in deformities is essential to understand the relationship between skeletal malformations and chemicals

correlated with deformity. Further studies to determine the various parameters related skeletal deformity is needed.

ACKNOWLEDGEMENTS

This research was supported by the Korean Ministry of Agriculture, Food and Rural Affairs, the Korean Ministry of Oceans and Fisheries, the Korean Rural Development Administration, and the Korean Forest Service under grant (number: 213008-05-1-WT511).

REFERENCES

- Aida K, Kato T, Awaji M (1984) Effects of castration on the smoltification of precocious male masu salmon, *Oncorhynchus masou*. Bull Jap Soc Sci Fish 50:565-571.
- Baeverfjord G, Asgard T, Shearer KD (1998) Development and detection of phosphorus deficiency in Atlantic salmon, *Salmo salar* L. parr and post-smolts. Aquac Nutr 4:1-11.
- Barahona-Fernandes MH (1982) Body deformation in hatchery reared European sea bass *Dicentrarchus labrax* (L). types, prevalence and effect on fish survival. J Fish Biol 21:239-249.
- Cahu C, Infante JZ, Takeuchi T (2003) Nutritional components affecting skeletal development in fish larvae. Aquaculture 227:245-258.
- Chen HY, Tsai JC (1994) Optimal dietary protein level for the growth of juvenile grouper, *Epinephelus malabaricus*, fed semipurified diets. Aquaculture 119:265-271.
- Cho HC, Kim JE, Kim HB, Baek HJ (2015) Effects of water temperature change on the hematological responses and plasma cortisol levels in growing of red spotted grouper. *Epinephelus akaara*. J Reprod Dev 19:19-24.
- Cruz-Lacierda ER, Toledo JD, Tan-Fermin JD, Burreson EM (2000) Marine leach (*Zeylanicobdella arugamensis*) infestation in cultured orange-spotted grouper,

- Epinephelus coioides*. Aquaculture 185:191-196.
- Fukuhara O, Fushimi T (1988) Fin differentiation and squamation of artificially reared grouper, *Epinephelus akaara*. Aquaculture 69:379-386.
- Guerreiro PM, Fuentes J, Canario AVM, Power DM (2002) Calcium balance in sea bream (*Sparus aurata*): The effect of oestradiol-17 β . J Endocrinol 173:377-385.
- Kayano Y (1988) Development of mouth parts and feeding in the larval and juvenile stages of red spotted grouper *Epinephelus akaara*. Bull Okayama Pref Fish Exp Stn 3:55-60.
- Kobayashi Y, Mikuni T (1987) A fundamental and clinical study of ferritin 'Eiken' radioimmunoassay kit. Radioisotopes 36(1):28-31.
- Lall SP, Lewis-McCrea LM (2007) Role of nutrients in skeletal metabolism and pathology in fish. Aquaculture 267:3-19.
- Lewis-McCrea LM, Lall SP (2007) Effects of moderately oxidized dietary lipid and the role of vitamins E on the development of skeletal abnormalities in juvenile Atlantic halibut (*Hippoglossus hippoglossus*). Aquaculture 262: 142-155.
- McGilvray F, Chan TT (2002) The trade in live reef foodfish: A Hongkong perspective. Aquaculture Asia 7:21-26.
- Mito S, Ukawa M, Higuchi M (1967) On the larval and young stages of a serranid fish, *Epinephelus akaara* (Temminck et Schlegel). Bull Naikai Reg Fish Res Lab 25:337-347.
- Nagano N, Hozawa A, Fujiki W, Yamada T, Miyaki K, Sakakura Y & Hagiwara A (2007) Skeletal development and deformities in cultures larval and juvenile seven-band grouper, *Epinephelus septemfasciatus* (Thunberg). Aquacult Res 38:121-130.
- Ogino C, Takeda H (1976) Mineral requirements in fish. III. Calcium and phosphorus requirements in carp. Bull Jap Soc Sci Fish 42:793-799.
- Park JY, Han JE, Kim KH, Cho JK, Myeong JI, Park JM (2016) Early osteological development of larvae and juveniles in red spotted grouper, *Epinephelus akaara*. Dev Reprod 20:87-101.
- Persson P, Bjornsson BT, Takagi Y (1999) Characterisation of morphology and physiological actions of scale osteoclasts in the rainbow trout. J Fish Biol 54:669-684.
- Roy PK, Lall SP (2003) Dietary phosphorus requirement of juvenile haddock (*Melanogrammus aeglefinus* L.). Aquaculture 221:451-468.
- Sakamoto S, Yone Y (1978) Effect of dietary phosphorus level on chemical composition of red sea bream. Bull Jap Soc Sci Fish 46:1227-1230.
- Sasayama Y (1999) Hormonal control of Ca homeostasis in lower vertebrates: considering the evolution. Zoolog Sci 16:857-869.
- Setiadi E, Tsumura S, Kassam D, Yamaoka K (2006) Effect of saddleback syndrome and vertebral deformity on the body shape and size in hatchery-reared juvenile red spotted grouper, *Epinephelus akaara* (Perciformes: Serranidae): a geometric morphometric approach. Jap J Ichthyol 22:49-53.
- Song YB, Oh SR, Seo JP, Ji BG, Lim BS, Lee YD, Kim HB (2005) Larval development and rearing of long-tooth grouper *Epinephelus bruneus* in Jeju Island, Korea. J World Aquac Soc 36:209-216.
- Sugama K, Ikenoue H (1999) Research and development: the seed production of humpback grouper, *Cromileptes altivelis*. JICA 54.
- Suzuki N, Suzuki T, Kurokawa T (2000) Cloning of a calcitonin gene-related peptide receptor and a novel calcitonin receptor-like receptor form from the gills of flounder, *Paralichthys olivaceus*. Gene 244:81-88.
- Van Den Avyle MJ, Garvick SJ, Blazer VS, Hamiltro SJ, Brumbaugh WG (1989) Skeletal deformities in small-mouth bass, *Micropterus dolomieu*, from southern appalachian reservoirs. Arch Environ Contam Toxicol 18: 688-696.